Inflammatory Myofibroblastic Tumor of Thigh: A Case Report and Review of Literature

Tapan Kumar Sahoo[1], Ipsita Dhal[2], Chandra Prava Mishra[2], Saroj Kumar Das Majumdar[3], Dillip Kumar Parida[4]

[1]Senior Resident, Department of Radiation Oncology, All India Institute of Medical Sciences, Bhubaneswar, Odisha, India, [2]Postgraduate, Department of Pathology, Shrirama Chandra Bhanj Medical College, Cuttack, Odisha, India, [3]Assistant Professor, Department of Radiation Oncology, All India Institute of Medical Sciences, Bhubaneswar, Odisha, India, [4]Professor and Head, Department of Radiation Oncology, All India Institute of Medical Sciences, Bhubaneswar, Odisha, India

Abstract

Inflammatory myofibroblastic tumor (IMT)is a rarely reported tumor of unknown etiology and pathogenesis. Neoplastic growths of myofibroblast, on a background of plasma cell and lymphocytic proliferation, have been designated as IMT. It occurs primarily in the lungs but has occurred in other extra-pulmonary sites, also. Abdomen is the most common extra-pulmonary site. The biological behavior is still uncertain. We report a case of 56-year-old man presenting with a lump over left thigh for 6 months. Post-excision histopathological examination showed possibility of IMT or spindle cell sarcoma. Immunohistochemical examination showed CD34, S-100, bcl2, and ALK1 negative, also smooth muscle actin positive focally and KI67 positive focally 30% favoring IMT.

Keywords: Immunohistochemistry, Inflammatory myofibroblastic tumor, Neoplastic growth, Thigh

INTRODUCTION

Inflammatory myofibroblastic tumor (IMT)is a rare neoplasm that consists of spindle cell proliferation with a distinctive fibroinflammatory and even pseudosarcomatous appearance.[1] IMT affects both sexes equally and is more prevalent in children and young adults.[2] These tumors most frequently occur in the lungs.[1] Only a few extra-pulmonary lesions such as liver, genitor-urinary tract, mesentery, omentum, extremities, head and neck, orbit, nasal sinuses, liver, spleen, pancreas, bowel, kidney, urinary bladder, testis, heart, and lymphatic systems have been reported.[1] Microscopic examination showed presence of histiocytes, fibroblasts, inflammatory cells, collagen bundles and plasma cells (Figures 1-3). We describe a patient with soft tissue IMT of left thigh who underwent surgery and post-operative radiotherapy.

Access this article online

Website: www.ijss-sn.com

CASE REPORT

A 56-year-old man initially presenting with growth over left thigh since 12 months which gradually increase in size to the present size (3 cm × 3 cm), non-tender, hard in consistency, there is no superficial venous engorgement and no local rise of temperature. Fine-needle aspiration cytology from the lesion revealed benign spindle cell lesion. Further investigation ruled out possibility of distant metastasis. Wide local excision was done under general anesthesia. The histopathological examination showed possibility of IMT or spindle cell sarcoma. Immunohistochemical examination showed CD34, S-100, bcl2, and ALK1 negative, also smooth muscle actin positive focally and KI67 positive focally (30%)favoring IMT. Post-operative computed tomography (CT) scan showed mild soft tissue thickening with a small collection. He was received external beam radiotherapy of 60 Gy in 30 fractions to left thigh with two opposing portals

Corresponding Author:
Dr. Tapan Kumar Sahoo, Senior Resident, Department of Radiation Oncology, All India Institute of Medical Sciences, Bhubaneswar - 751 019, Odisha, India. Phone: +91-9437219525. E-mail: drtapankumars8@gmail.com

and shrinking field technique, by cobalt 60 teletherapy machine and tolerated well to radiotherapy. Post treatment clinical examination of the left lower limb showed scar healthy with no growth or induration (Figure 4). Now, he is on regular follow-up without any loco-regional recurrence or distant metastasis since 13 months.

DISCUSSION

Because of the wide spectrum of its histological and clinical appearance, this tumor has several synonyms including fibrous xanthoma, plasma cell granuloma, pseudosarcoma, lymphoid hamartoma, myxoidhamartoma, inflammatory myofibroblastic proliferation, benign myofibroblastoma, inflammatory fibrosarcoma, xanthoma, histicytoma, xanthogranuloma, post-inflammatory tumor, and inflammatory pseudotumor, and was renamed "IMT" in the 2002 World Health Organization classification of soft tissue tumours.[3]

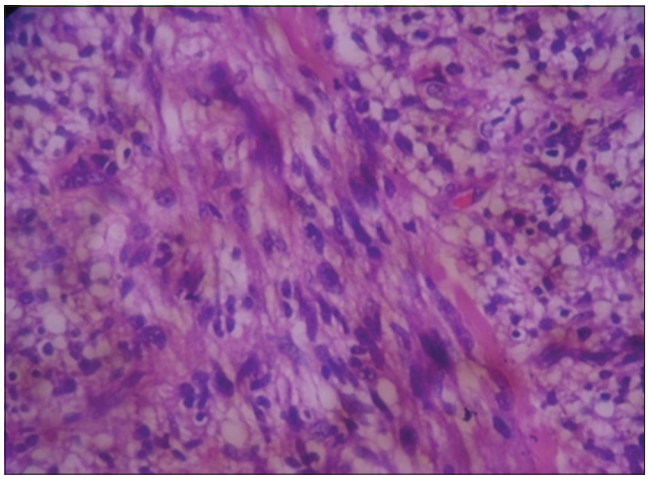

Figure 1: Presence of fibroblasts along with histiocytes in sheets (H and N, ×400)

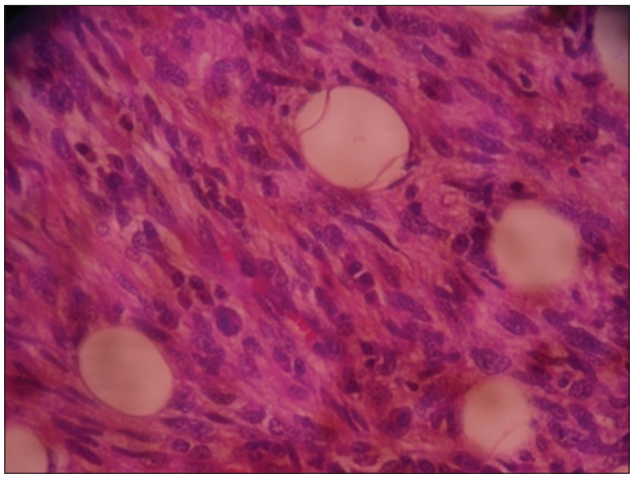

Figure 2: Presence of plasma cells and fibroblasts (H and N, ×400)

IMTs have been suggested to result from trauma, operation, infection, local irritation, or neoplasm, but their actual etiology remains unknown.[4] Although essentially considered benign lesions, IMTs may recur, metastasize, or undergo malignant transformation.[1] The most prevalent symptoms are fever, weight loss, and constitutional symptoms, which regress after excision. Macroscopically, it is a well-defined mass. CT scan and/or magnetic resonance imaging of IMT usually show a well-defined mass. Based on clinical and radiological data it is difficult to differentiate between IMT and neoplasm.

For therapeutic strategy and prognosis, biopsy with detailed pathological examination is essential. Based on immunological staining, positivity for vimentin, smooth muscle actin or cytokeratin consistent with myofibroblasts could be helpful to establish a diagnosis.[1] The histological differential diagnosis of IMT is extensive, and includes benign and malignant spindle cell tumors such as nodular fasciitis, solitary fibrous tumor, benign fibrous histiocytoma, calcifying fibrous tumor, myofibroma, fibrosarcoma, follicular dendritic cell tumor, and leiomyosarcoma.

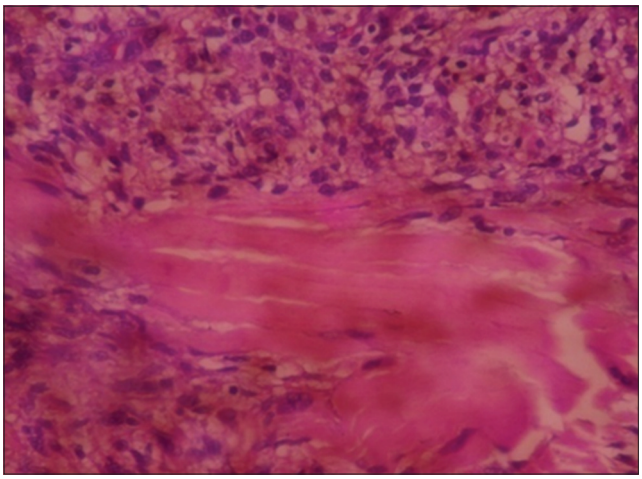

Figure 3: Presence of inflammatory cells, histiocytes, collagen bundle at centre (H and N, ×400)

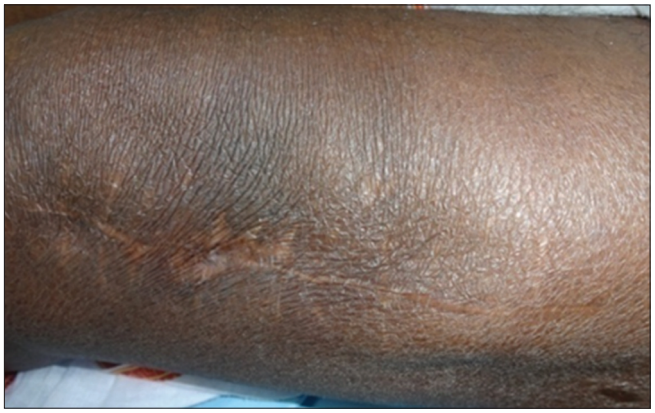

Figure 4: Post-operative, post-radiotherapy limb showing scar healthy without any local growth

Histologically, IMTs contain much more prominent inflammatory infiltrate than nodular fasciitis.[5] In addition, they lack the "c" shaped fascicles, and mucin-rich stroma that is responsible for the characteristic "tissue culture-like or feathery" appearance in nodular fasciitis.[6] Solitary fibrous tumor was excluded due to lack of hemangiopericytoma-like areas and strong CD34 immunoreactivity.[7] The diagnosis of benign fibrous histiocytoma was not favored because of the lack of characteristic storiform pattern.[8] Calcifying fibrous tumor, a rare benign neoplasm, is uniformly hypocellular and contains scattered dystrophic calcification.[2] The diagnosis of myofibroma was excluded due to lack of biphasic growth pattern with hemangiopericytoma-like blood vessels.[9] Fibrosarcoma was excluded due to lack of malignant features, collagenous areas herringbone pattern that characterize it. Additionally, it typically lacks a significant inflammatory infiltrate.[9] Follicular dendritic cell tumor is differentiated from IMTs by its characteristic distribution of inflammatory infiltrate admixed with dendritic spindle cells. It is easily distinguished by immunohistochemical staining for CD21, CD23 and/or CD35.[5] If there was a predominant lymphocytic and/or plasmacytic component, a plasma cell neoplasm or lymphoma should be excluded. In our case, the immunohistochemical analysis revealed CD34, S-100, bcl2, and ALK1 negative, also smooth muscle actin positive focally and KI67 positive focally 30% favoring IMT. According to the histological and immunohistochemical features of the present case, a final diagnosis IMT was made.

IMTs are tumors with unpredictable clinical behavior, requiring complete surgical excision and continuous monitoring of clinical consequences. According to the World Health Organization IMTs are classified as tumors of intermediate biological potential due to a tendency of local recurrence and small risk of distant metastasis.[5] Surgical resection remains the recommended treatment for IMT. Prognosis is excellent when the tumor is completely removed. Recurrence has been reported in 15-37% of abdominal IMT.[1] Radiotherapy, chemotherapy, or steroid treatment has been reported to successfully treat some patients, but benefits have not been proven in a large series of patients.[10]

CONCLUSIONS

IMT is a rare spindle cell tumor with an uncertain malignant potential. Thus, early recognition and complete surgical resection are necessary to avoid recurrences and prevent the spread of locally aggressive tumors. Soft tissue IMT in thigh is a rare disease and represents a diagnostic dilemma for surgeons. Due to nonspecific radiological and clinical presentations, diagnosis of IMT is rarely made before excision. The diagnosis is dependent on histological and immunohistochemical examination. Surgical resection remains the recommended treatment for IMT. Close follow-up is recommended to prevent recurrence.

REFERENCES

1. Coffin CM, Watterson J, Priest JR, Dehner LP. Extrapulmonary inflammatory myofibroblastic tumor (inflammatory pseudotumor). A clinicopathologic and immunohistochemical study of 84 cases. Am J Surg Pathol 1995;19:859-72.
2. Roberts G, Farrell M, Allcutt D. Spinal inflammatory pseudotumours. Br J Neurosurg 2001;15:197-8.
3. Aizawa T, Sato T, Tanaka Y, Kishimoto K, Watanabe M, Kokubun S. Intramedullary plasma cell granuloma in the cervicothoracic spine. Case report. J Neurosurg 2002;97:235-8.
4. Allanore Y, Pham XV, Clerc DA, Menkès CJ, Kahan A. Sacral inflammatory pseudotumor revealed by paraneoplastic syndrome. Rheumatol Int 2004;24:166-8.
5. Gleason BC, Hornick JL. Inflammatory myofibroblastic tumours: where are we now? J Clin Pathol 2008;61:428-37.
6. Dayan D, Nasrallah V, Vered M. Clinico-pathologic correlations of myofibroblastic tumors of the oral cavity: 1. Nodular fasciitis. J Oral Pathol Med 2005;34:426-35.
7. Shimoyama T, Horie N, Ide F. Solitary fibrous tumor of the palate: a case report and review of the literature. J Oral Maxillofac Surg 2004;62:895-7.
8. Alves FA, Vargas PA, Coelho Siqueira SA, Coletta RD, de Almeida OP. Benign fibrous histiocytoma of the buccal mucosa: Case report with immunohistochemical features. J Oral Maxillofac Surg 2003;61:269-71.
9. Neville B, Damm D, Allen C, Bouquot J. Oral and Maxillofacial Pathology. 3rd ed. Philadelphia: W.B. Saunders; 2008.
10. Cho YS, Kim SM, Chung WH, Hong SH. Inflammatory pseudotumour involving the skull base and cervical spine. J Laryngol Otol 2001;115:580-4.

How to cite this article: Sahoo TK, Dhal I, Mishra CP, Majumdar SK, Parida DK. Inflammatory myofibroblastic tumour of thigh: A case report and review of literature. Int J Sci Stud 2014;2(8):261-263.

Source of Support: Nil, **Conflict of Interest:** None declared.