Print ISSN: 2321-6379
Online ISSN: 2321-595X

Original Article

Lower Lip and Angle Reconstruction after Post-excisional Defects

K Surendra Mannan[1], Utpal Kumar Bordoloi[2], Deepthi Patil Kulkarni[3]

[1]Mch 2-year Student, Department of Plastic and Reconstructive Surgery, Assam Medical College and Hospitals, Dibrugarh, Assam, India, [2]Professor and Head, Department in Plastic and Reconstructive Surgery, Assam Medical College and Hospitals, Dibrugarh, Assam, India, [3]Mch 1-Year Student, Department of Plastic and Reconstructive Surgery, Assam Medical College and Hospitals, Dibrugarh, Assam, India

Abstract

Introduction: Reconstruction of lower lip after post-excisional defects, entails both cosmetic and functional dimensions. Some of the proliferative conditions such as squamous hyperplasia, squamous papilloma, squamous cell carcinoma, chronic hypertrophic candidiasis, actinic cheilitis, and vascular malformations are suitable for reconstruction using local tissues for best cosmetic and functional results.

Materials and Methods: A case study of 13 cases of lower lip and angle of mouth post-excisional defects was reconstructed in the plastic surgery department of AMCH in a year from 2022 to 2023.

Results: Out of 13 cases, the following reconstruction was performed with 3 month to 1 year follow-up. Techniques employed were excision with primary closure and local flaps such as Abbe Estlander flap, double and single Rhomboid flap, McGregor or Gilles fan flap, Webster flap, Step ladder flap, and Nasolabial flap.

Conclusion: Availability of local tissue, cheek and remaining lip post excision, makes it as a first choice in reconstruction of lower lip and angle.

Key words: Lower lip, Post-excisional defects, Proliferative conditions

INTRODUCTION

As lips have significant functional and esthetic importance. Even subtle changes in the appearance of the vermilion border, labial commissures, or Cupid's bow are readily visible to the casual observer, and deformity can have a profound and lasting effect on the patient's self-image and quality of life.[1]

The inferior margin of the lower lip is defined by the mental crease (labiomental crease) that separates the lip from the chin.[2] The upper and lower lips differ in that the lower lip is composed of a single esthetic unit while the upper lip has multiple subunits.

Surgical treatments aim to avoid local recurrence and to obtain satisfactory functional and esthetic outcomes. In lower lip reconstruction, however, there are more than 200 surgical techniques. Besides, the operative methods should be determined considering various factors such as the location and size of the lesion and the range of resection. Therefore, the optimal reconstruction method[3] varies from case to case.

In general, in cases of small lesions where the defect is full thickness and <1/3rd of total lip length for the lower lip and 1/4th for the upper lip; primary closure can be performed synchronously with excision. Several types of surgical techniques, including V-shaped resection, W-shaped resection, flared W-plasty, and barrel-shaped excision, can be applied to these cases. Barrel-shaped excision has been used most frequently.[4]

On the other hand, defects more than 1/3rd; techniques such as Abbe Estlander flap, Modified Webster flap, McGregor or Gilles fan flap, Step ladder flap, Nasolabial flap, and for the angle of mouth defects; double rhomboid flap was performed with good sphincter function. Therefore, these surgical treatments can be used as a first line of choice for large defects, for which primary closure cannot be performed following a resection.

Access this article online

www.ijss-sn.com

Month of Submission : 09-2023
Month of Peer Review : 09-2023
Month of Acceptance : 10-2023
Month of Publishing : 11-2023

Corresponding Author: K Surendra Mannan, Department of Plastic and Reconstructive Surgery, Assam Medical College and Hospitals, Dibrugarh, Assam, India.

MATERIALS AND METHODS

Thirteen patients were studied from a period between January 2022 and January 2023, among the total patients, two cases underwent Estlander flap (n = 2), one case with McGregor/Gilles fan flap (n = 1), one case with Webster flap (n = 1), four cases with single or double rhomboid flap (n = 4), two cases with step ladder flap technique (n = 2), one case by nasolabial flap (n = 1) and two patients having defect <1/3rd, primary barrel shaped excision and closure was done (n = 2). The cases presented here had proliferative lesions of the lower lip such as squamous hyperplasia, squamous papilloma, solar (actinic cheilitis), chronic hypertrophic candidiasis, and vascular malformations and all were suitable for repair using local tissue from the remaining lip and cheek.

The follow-up period ranged from 12 to 14 months. Patients underwent pre-operative biopsy, and imaging studies including neck computed tomography, USG neck, and other routine investigations.

Surgical Techniques

There are numerous flaps described in the literature for the reconstruction of acquired lip defects. Factors deciding the choice of the reconstruction procedure depend on; whether the defect is limited to mucosa, skin or extends to the underlying muscle, will the planned outcome is going to be static or dynamic, and most importantly whether the flap taken for reconstruction is from remaining lip element or adjacent cheek used for reconstruction.[5]

The different options of reconstruction vary from simple primary closure of the defect to local flaps such as Abbey Estlander flaps [Figure 1], McGregor or Gilles fan flaps [Figure 2], single and double rhomboid flaps [Figure 3], Bernard Webster flap [Figure 4], step ladder flap [Figure 5], and Nasolabial flap [Figure 6].

This descriptive case study was done in a tertiary care center, Assam; over 1 year from 2022 to 2023 to evaluate the types of post-excision lower lip defects encountered and the different treatment modalities used for its reconstruction. This article also discusses the applications of different flap designs used in the reconstruction of various lip defects.

Figure 1: Abbé-Estlander Flap

RESULTS

A total of 13 patients were studied and underwent procedures. Male preponderance [Table 1] was seen and

Table 1: Gender

Age	Mean±SD
	58.85±4.45

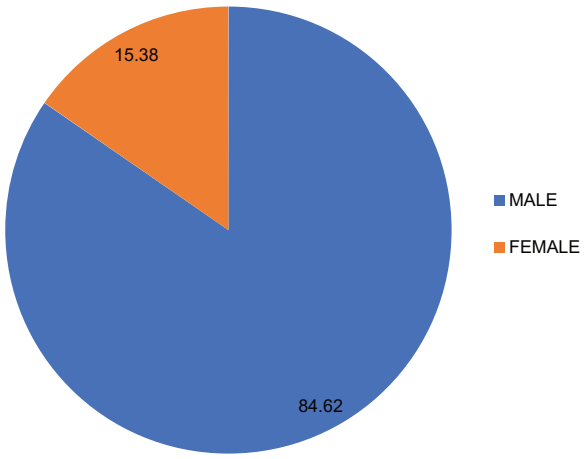

Table 2: HPE diagnosis

Diagnosis	Number	Percentage
Squamous cell carcinoma	5	38.46
Actinic cheilitis	2	15.38
Squamous hyperplasia	2	15.38
Squamous papilloma	2	15.38
Chronic hypertrophic candidiasis	1	7.69
Vascular malformation	1	7.69
Total	13	100.00

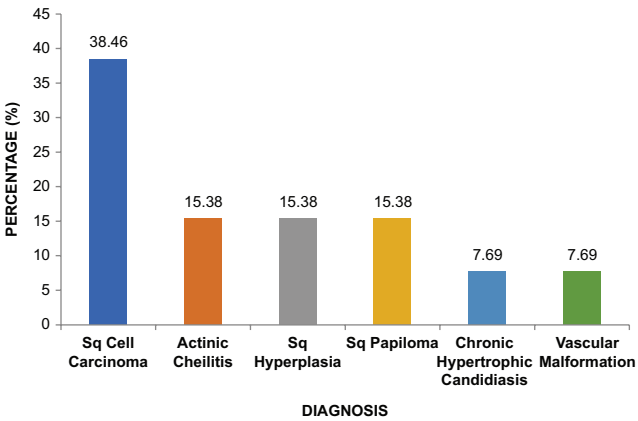

all had lower lip reconstruction for various acquired defects from the period of January 2022–December 2023.

The age of the patients ranged from 52 to 68 years and out of these cases, the proliferative lesions of the oral cavity [Table 2] were more common and the defects created post-excision were managed with reconstruction using local tissues from the remaining lip and cheek.

The choice of reconstruction technique was based on the institutional protocol. The protocol used was primarily dependent on the volume/extent of the lip defect. Other secondary variables considered in choosing the modality of reconstruction included the age of the patient, elasticity of tissues, comorbidities, and patient compliance.

DISCUSSION

Lip neoplasms are more common in the lower lip and benign proliferative lesions such as squamous hyperplasia, squamous papilloma, solar (actinic cheilitis), and hypertrophic candidiasis are more suitable for reconstruction with local tissues post-excision. The primary goal in labial reconstruction includes the restoration of the esthetic and function of the lips as well as the restoration of oral sphincter competence with minimal esthetic functional alterations.

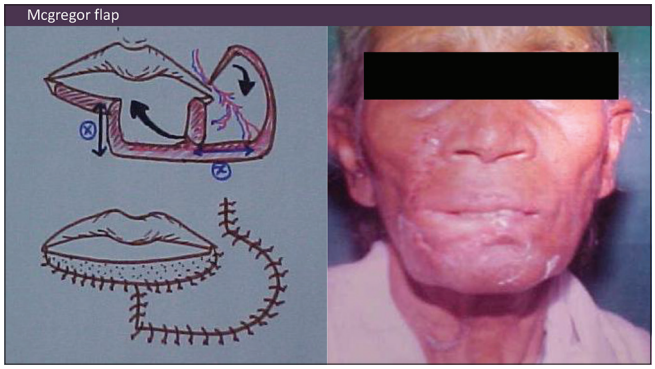

Figure 2: Mcgregor Flap

When planning a lower lip repair, it is necessary to evaluate the extent of tissue loss to be reconstructed. The repair of full-thickness defects requires an accurate approximation of the three tissue layers: Mucosa, muscle, and skin. Wedge or V-shaped, barrel-shaped resection and primary closure are more suitable for defects <1/3rd. However, tissue losses >1/3rd of the area require complex reconstructions and more elaborate surgical planning.

To facilitate systematization, injuries are classified according to their location in the commissure and are divided into defects that affect or approach the commissure and defects that are limited to the central lip.[1]

In patients with almost a total defect of the lower lip, we used the Webster–Bernard flap, which involved the medial advancement of the cheek tissue to create a new lower lip. In 1853, Bernard[6] presented a technique that involved triangular resection of the bilateral Burrow flap in the nasolabial folds. Subsequently, this procedure underwent modification by Ginestet and Landwerlin[7] in 1946, Freeman[8] in 1958, and Webster *et al.*,[9] in 1960. According to the Webster technique, the orbicularis and buccinator muscles are incised laterally to the commissure to advance the lower lip reconstruction.[10] Modification of this technique was described by Spinelli *et al.* who advocated the removal of a U-shaped area of cheek tissue adjacent to ala to minimize the post-operative scarring.[11]

In patients with defects approaching commissure along with more than 1/3rd of lower lip defect, Abbe Estlander flap was used. In 1872, Estlander[12] described the original

Figure 3: Double Rhomboid Flap

technique for reconstructing these defects. Reconstruction of the lower lip involved the rotation of a lateral area of the upper lip to the commissure. The modified Estlander flap is based more medially on the initially proposed flap and seeks to avoid lip commissure deformations. A commissuroplasty using the Converse[12] technique is performed that aims to restore the usual form of the commissure and the normal fading of the vermilion. A triangle of skin and subcutaneous tissue is excised at the point corresponding to the position of the contralateral normal commissure.

Figure 4: Webster Modification of Bernard Flap

The defects close to the corner of the mouth can be reconstructed using a Gillis fan flap.[13] Gillis flap essentially is an advancement of residual ipsilateral lip into the defect. It can be harvested as a unilateral or a bilateral flap depending upon the size of the defect being reconstructed. The Gillis flap provides an excellent option for the reconstruction of the lower lip.

Frequently, a defect is too wide to close directly but is not wide enough to require a flap such as the Estlander flap.

Figure 5: Step ladder method of Johanson

Figure 6: Nasolabial Flap

Johanson *et al.*[14] proposed the stair-step advancement flap for such a defect. This technique is capable of reconstructing defects extending to as much as two-thirds of the lower lip. When the defect is located laterally, the step incision is outlined exclusively on the remaining long side of the lip. Each of the rectangles and the triangle are excised through the full thickness of the lower lip. This allows advancement of the flap in the direction of the defect with each succeeding higher step in the staircase, and the wound is closed in layers.

Thus, a dynamic reconstruction with remaining lip tissue can provide superior results in terms of lip appearance and function in smaller lip defects. Reconstruction of large-scale post-excisional defects often required the use of local tissue flaps that provided static support of the lip with excellent esthetic outcomes. A certain degree of microtomy can be corrected as a secondary procedure if required.

CONCLUSION

It is always preferable to use local tissue, from the remaining lips and adjacent cheek to reconstruct post-excisional defects of the lower lip. This descriptive case study presented a simplified, systematic, and literature-based strategy for planning lower lip reconstructions using efficient and reproducible techniques for training resident physicians in the treatment of complex lower lip lesions based on the extent of tissue loss, to yield appropriate esthetic and functional results.

REFERENCES

1. Neligan PC. Strategies in lip reconstruction. Clin Plast Surg 2009;36:477-85.
2. Renner G. Reconstruction of the lip. In: Baker S, Swanson N, editors. Local Flaps in Facial Reconstruction. New York: Mosby; 1995.
3. Brusati R. Reconstruction of labial commissure by a sliding U-shaped cheek flap. J Maxillofac Surg 1979;7:11-4.
4. Mazzola RF, Lupo G. Evolving concepts in lip reconstruction. Clin Plast Surg 1984;11:583-617.
5. Baumann D, Robb G. Lip reconstruction. Semin Plast Surg 2008;22:269-80.
6. Bernard C. Lower lip cancer operates by a new procedure. Bull Mem Soc Chir Paris 1853;3:357.
7. Ginestet G, Landwerlin F. Three cases of permanent constriction of the jaws of joint or para-articular bone origin. Rev Odontostomatol 1946;2:197-201.
8. Freeman BS. Myoplastic modification of the Bernard cheiloplasty. Plast Reconstr Surg Transplant Bull 1958;21:453-60.
9. Webster RC, Coffey RJ, Kelleher RE. Total and partial reconstruction of the lower lip with innervated musclebearing flaps. Plast Reconstr Surg Transplant Bull 1960;25:360-71.
10. Unsal Tuna EE, Oksuzler O, Özbek C, Ozdem C. Functional and aesthetic results obtained by modified Bernard reconstruction technique after tumour excision in lower lip cancers. J Plast Reconstr Aesthet Surg 2010;63:981-7.
11. Spinelli HM, Tabatabai N, Muzaffar AR, Isenberg JS. Upper lip reconstruction with the alar crescent flap: A new approach. J Oral Maxillofac Surg 2006;64:1566-70.
12. Franc C, Braye F, Breton P, Freidel M. The Abbe-Estlander flap: Anatomic basis, surgical technic and indications for lip repair. Rev Stomatol Chir Maxillofac. 1996;97:92-107.
13. Renner GJ, Zitsch RP 3rd. Reconstruction of the lip. Otolaryngol Clin North Am 1990;23:975-90.
14. Johanson B, Aspelund E, Breine U, Holmström H. Surgical treatment of non-traumatic lower lip lesions with special reference to the step technique: A follow-up on 149 patients. Scand J Plast Reconstr Surg 1974;8:232-40.

How to cite this article: Mannan KS, Bordoloi UK, Kulkarni DP. Lower Lip and Angle Reconstruction after Post-excisional Defects. Int J Sci Stud 2023;11(8):25-29.

Source of Support: Nil, **Conflicts of Interest:** None declared.