Print ISSN: 2321-6379
Online ISSN: 2321-595X
DOI: 10.17354/ijss/2017/353

Original Article

Utility of 128-slice Multi-detector Spiral Computed Tomography in Detecting Spectrum of Involvement in Acute Pancreatitis

Bharatkumar Mudalgi[1], Manohar Kachare[2], Akshay Kulkarni[3]

[1]Associate Professor, Department of Radiology, Miraj-Pandharpur Road, Government Medical College, Miraj, Maharashtra, India, [2]Professor, Department of Radiology, Miraj-Pandharpur Road, Government Medical College, Miraj, Maharashtra, India, [3]Senior Resident, Department of Radiology, Miraj-Pandharpur Road, Government Medical College, Miraj, Maharashtra, India

Abstract

Introduction: Computed tomography (CT) has proved to be invaluable, noninvasive, technique for detailed assessment of pancreas during its acute inflammatory stage. Detailed evaluation, proper staging on scoring basis and prediction of morbidity and mortality are possible with the help of advanced high-resolution multi-detector multislice CT scanner. The purpose of this study is to determine the role and efficacy of CT scan in evaluating spectrum of extent of involvement of pancreas in acute phase irrespective of the etiology. This was a cross-sectional retrospective study of 3 years duration.

Aims and Objectives: To evaluate the extent of involvement of pancreatic parenchyma in acute phase of parenchymal inflammation and to diagnose common early and late complications with the prediction of morbidity and mortality.

Material and Methods: This was a cross-sectional retrospective study conducted at Government Medial College, Miraj, from June 2014 to May 2017. A total of 150 patients of different age groups presenting with signs and symptoms of acute pancreatitis and with those with altered pancreatic function test were included in this study. Diagnosis was confirmed on clinical, biochemical marker (raised serum amylase and lipase levels), imaging findings and response to the treatment.

Results: In our study, acute pancreatitis was more common in males (68%) compared to female population (32%). Most common age group affected by this pathology was 40-60 years age group (58%), and least common age group was more than 80 years (<7%). Most common etiology in males was alcohol abuse (39%) and in females were gall stones (39%). 20-40 age group population was most commonly affected by alcohol induced pancreatitis while 40-60 age group was most commonly affected by gall stones disease. Other causes were seen in <40 age group.

The most common finding of acute pancreatitis on CT scan was acute early interstitial edematous pancreatitis (31.4%). Ductal disruption was the least common finding (2%). CT severity index was mild in 38% cases and moderate to severe in 31% each.

Conclusion: Early diagnosis and assessment of extent of parenchymal involvement with an assessment of complication and prediction of morbidity and mortality clearly remains a challenge in acute pancreatitis. CT proves itself as a gold standard in such emergency situation and a true winner above all other modalities thus helping the physicians in quality result oriented care of these patients.

Key words: Complication, Computed tomography, Computed tomography severity index, Pancreas, Prognosis, Radiological diagnosis

Access this article online

www.ijss-sn.com

Month of Submission : 05-2017
Month of Peer Review : 06-2017
Month of Acceptance : 07-2017
Month of Publishing : 07-2017

INTRODUCTION

Continuous radiological innovations have led to availability of high end, state of art, multi-detector, multislice, and spiral computed tomography (CT) scanners for regular use in clinical practice to evaluate each organ in detail with the highest spatial and temporal resolution with minimal

Corresponding Author: Bharatkumar Mudalgi, "Adi-Siya" Bunglow, Dhananjay Housing Society, Behind Civil Hospital, Sangli, Maharashtra, India. Phone: +91-7875714904. Tel.: +233-2326823. E-mail: drbharat76@gmail.com

possible dose and time for the investigation. These non-invasive techniques are extremely helpful not only to image organ with small possible slice thickness (up to 0.6 mm) but also has helped us to detect most of the early as well as late complications of inflammation of pancreas. Of course, the credit goes to a number of scientists for their contribution from advent of remarkable technology to till date modification and innovations resulting in making these user-friendly Softwares. At this background, it's also necessary to remember and salute Godfrey Hounsfield of UK who introduced this technology in 1972 on the basis different of number mathematical equations and algorithms and made an important historic development which further evolved till date into high end scanners in terms of slices, source (single or dual source), detector dynamics and fast iterative reconstruction reducing remarkably the scan times and increasing the resolution as well as the patient throughput in the department of radiology. These technical advantages have help the radiologist and physician to evaluate the pancreatic parenchyma which was the most difficult retroperitoneal organ to image with conventional imaging.

Acute pancreatitis is a common problem with varied etiology and extent of involvement. Acute pancreatitis refers to an acute inflammation of pancreatic parenchyma due to the injury of pancreatic acinar cells with multifactorial etiology. CT imaging is extremely useful for confirming diagnosis and to see for the degree of parenchymal injury with prediction of morbidity and mortality on the basis of modified CT severity index (CTSI). New Atlanta classification can also be used for proper nomenclature of the pathological involvement on CT scan and properly classify pancreatitis as well as a decrease in inter radiologist variations. US and magnetic resonance imaging (MRI) have limited abilities for detailed evaluation of this retroperitoneal organ. The aims and objective of this study are to determine the efficiency of CT scan in evaluating the spectrum of involvement of pancreas, properly classifying them and predicting the severity of the disease for prognostication of this life-threatening disease.

MATERIAL AND METHODS

This was a cross-sectional retrospective study conducted at Government Medial College, Miraj, from June 2015 to May 2017. A total of 150 patients of different age groups presenting with signs and symptoms of acute pancreatitis and with those with altered pancreatic function test were included in this study. Diagnosis was confirmed on clinical, biochemical marker (raised serum amylase and lipase levels), imaging findings and response to the treatment.

Study Area

The study area includes Miraj city and districts in vicinity including peripheral small town and villages.

Study Population

A total of 150 patients of varied age groups presenting with clinical signs and symptoms of acute pancreatitis with raised serum amylase and lipase levels were included in the study.

Inclusion Criteria

- Patients referred for CT of pancreas, who were highly suspected to have acute inflammation.
- Patient who were already diagnosed pancreatitis and were scanned to assess the extent of complications.

Exclusion Criteria

- Patient who were known the case of chronic pancreatitis.
- Patients presenting with altered renal functions in whom only plain scan was performed.
- Patient with contrast allergy.
- Scans with poor image qualities showing artifacts due to poor breath hold hampering optimal evaluation.

Equipment Used

Multi-detector (128-slice) spiral CT, siemens somatom definition AS+, siemens medical systems, Forchheim, Germany.

Protocol Used

Triphasic contrast study of abdomen and pelvis was performed after acquiring a topogram. Axial images were obtained, and the acquired data were reconstructed into isotropic coronal and sagittal planes. The slice thickness used was 0.6 mm. All these images were interpreted in arterial, venous and delayed phases. The contrast was injected using Dual Injector (Stellant, Medrad Dual Head Injector, USA). About 100 ml of non-ionic contrast (Iohexol 300 ml I/ml) was injected through antecubital vein at a flow rate of 4 ml/s followed by saline injection of 40 ml at 3.5 ml/s. Arterial phase images were acquired with a delay of 25-30 s using care bolus technique venous phase and delayed phase images were acquired at delay of 45-60 s and 120-140 s, respectively, after intravenous. Injection of contrast revised Atlanta classification 2012 was used for labeling correctly the pathologies of pancreas. Staging of disease was performed using modified CTSI which helped in predicting morbidity and mortality of the disease.

OBSERVATION

Axial CT scans with reconstruction in coronal and sagittal planes in arterial, venous and delayed phases

were performed in 150 patients who had a high index of suspicious of acute pancreatitis on the basis of clinical signs, symptoms and altered pancreatic function tests. The results are enumerated in Tables 1-5.

RESULTS

A total of 150 patients with a clinical and radiological diagnosis of pancreatitis were included in this study. There was clear sex predilection toward males with M:F ratio of 2:1. Of the total number, 102 (68%) were males and 48 (32%) were females as shown in Table 1. 40-60 age groups were more labile to pancreatitis than other age groups (Table 2). Alcohol abuse and gall stones were the most common etiological factors (39% each). However, alcohol abuse was most common causative agent in males (53 out of 59) and gall stones in females (34 out of 59). <4% had other rare causes of pancreatitis while no causative agent could be found in 14.7% case (Table 3). Alcohol induced pancreatitis was commonly seen at age group of 20-40 years irrespective of sex while gall stone pancreatitis was seen commonly at age group of 40-60 years (Table 4). Degree of involvement was tabulated using modified CTSI. About 38% patients had a mild degree of involvement while moderate to severe involvement was seen in 38% age. The prediction of morbidity and mortality is shown in Figure 1 as per CTSI. Most common CT imaging findings were acute interstitial edema of pancreas (31%). Various complications were enlisted (Table 5) in accordance with New Atlanta classification 2012 (Figure 2). Acute peripancreatic fluid collections (APFCs) were the most common complication (12.7%).

In most of the patient irrespective of age, sex who had a mild degree of pancreatitis according to modified CTSI the predicted morbidity and mortality was 3% and 8%, respectively (Table 6).

Table 1: Gender distribution

Gender	*n* (%)
Female	48 (32)
Male	102 (68)
Grand total	150 (100)

Table 2: Age and gender distribution

Age distribution	Female	Male	Total
1-20	11	31	42
20-40	9	16	25
40-60	22	36	58
60-80	5	15	20
80-above	3	4	7
Grand total	48	102	150

Table 3: Distribution by etiopathology

Etiology	Female	Male	Total (%)
Alcohol	6	53	59 (39)
Gallstones	34	25	59 (39)
Hypertriglyceridemia	2	3	5 (3.3)
Congenital anomalies	1	2	3 (2)
Trauma	0	3	3 (2)
Idiopathic	5	16	21 (14.7)

DISCUSSION

Acute pancreatitis is one of the most common causes of the upper abdominal pain, wherein the clinical signs and symptoms are insensitive to assess the degree of organ involvement and to predict morbidity and mortality.[1,2] The involvement of adjacent and remote tissue and organs also

Type of Pancreatitis	Fluid Collections
< 4 Weeks after Onset	
IEP	APFC
	Sterile
	Infected
Necrotizing Pancreatitis	ANC
	Parencymal necrosis alone
	Sterile
	Infected
	Peripancreatic necrosis alone
	Sterile
	Infected
	Pancreatic and peripancreatic necrosis
	Sterile
	Infected
≥ 4 Weeks after Onset	
IEP	Pancreatic pseudocyst
	Sterile
	Infected
Necrotizing Pancreatitis	WON
	Sterile
	Infected

Figure 1: Revised Atlanta classification of fluid collections in acute pancreatitis. ANC: Acute necrotic collection, APFC: Acute peripancreatic fluid collection, WON: Walled-off necrosis

Table 4: Age distribution of etiologies

Age range	Alcohol	Gallstones	Hypertriglyceridemia	Congenital anomalies	Trauma	Idiopathic
1-20	9	3	2	1	1	3
20-40	30	12	2	2	2	7
40-60	14	38	1	0	0	5
60-80	6	2	0	0	0	4
80-above	0	4	0	0	0	2
Grand total	59	59	5	3	3	21

has an alarming concern which needs to be addressed by robust and reliable imaging technique. The incidence of acute pancreatitis is 5-17 case per 100,000 per year. Biliary calculi are the most common cause in women and alcohol abuse is most common cause in men for acute as well as recurrent pancreatitis. Newer advanced CT imaging has emerged to be a gold standard in imaging of pancreas. To add on this CT technique has also proved a clear winner in predicting the causes of acute pancreatitis.[3] Clinical signs and symptoms along with three-fold rise in serum amylase and lipase and CT findings form a Tripod in confirming diagnosis of pancreatitis and its sequelae. Furthermore, biochemical markers are raised in other pathologies as well proving them to be very insensitive. Many systems to classify pancreatitis have been developed clinically such as Acute Physiology and Chronic Health Evaluation II (APACHE II), and Ranson's Criteria which predicts the severity of pancreatitis with a score of more than three indicating acute severe pancreatitis. However, their utility is debatable and less sensitive. CTSI is commonly used to evaluate and estimate pancreatic injury[1] and to predict morbidity and mortality (Figure 1). Algorithmic approach to the care of patients with necrotizing pancreatitis can be built up.[4]

The revised Atlanta classification (Figure 3) can be used precisely to describe findings in acute pancreatitis, standardize terminology across specialties and help in the treatment planning, defines acute pancreatitis as interstitial edematous pancreatitis or necrotizing pancreatitis.[10] It also categories the various pancreatic and peripancreatic collections and helps us to plan treatment depending on the stage of the disease.

Table 5: CT features of acute pancreatitis

Features	*n* (%)
Interstitial edema	47 (31.4)
Necrosis	19 (12.6)
Pancreatic abscess	7 (4.6)
Ductal disruption	3 (2)
Vascular thrombosis	17 (11.4)
Extrapancreatic fat necrosis	17 (11.4)
APFC	19 (12.7)
Pseudo cyst	16 (10.6)
WON	5 (3.3)

CT: Computed tomography, WON: Walled-off necrosis, APFC: Acute peripancreatic fluid collection

Table 6: Distribution of cases according to CT severity index with prediction of morbidity and mortality

Score	*n* (%)	Morbidity (%)	Mortality (%)
0-2 (mild)	57 (38)	3	8
4-6 (moderate)	46 (31)	6	35
8-10 (severe)	47 (31)	17	92

CT: Computed tomography

Proper Triphasic imaging protocols are extremely useful to study a variety of details regarding degree of involvement of pancreatic parenchyma, peripancreatic tissues and organs and surrounding arteriovenous luminal involvement. Noncontrast scans are often not useful especially to predict necrosis[2] and hence can prevent additional radiation exposure. Scanning using care bolus technique with injection delay of 25-30, 45-60 s, and 120 s help us in acquiring raw data in arterial, venous, and delayed phases.[1] This data are effectively reconstructed using 0.6 mm slice thickness in axial, coronal, and sagittal isotropic images. Although under debate, intravenous contrast usage clearly outweighs the potential risk of its injection.

Imaging Pearls

In interstitial edematous pancreatitis (Figure 4), this organ shows a diffuse enlargement with slight heterogeneous enhancement. These findings are more commonly seen

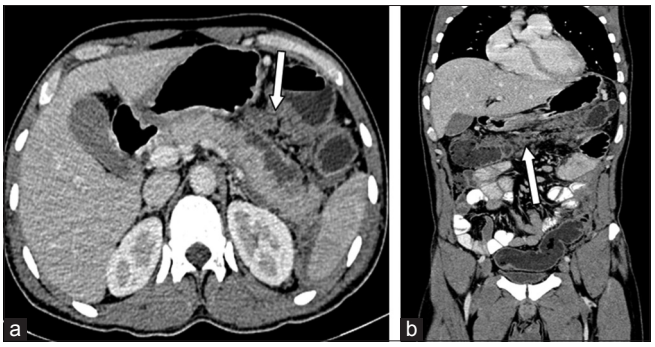

Figure 2: Contrast-enhanced computed tomography (CECT) in 46-year-old woman with epigastric pain. (a and b), Axial and coronal CECT venous phase image shows extrapancreatic fat necrosis/saponification noted in the lesser sac (long arrows, a and b)

Severity index	Percentage morbidity	Percentage mortality
0-3	8	3
4-6	35	6
7-10	92	17

Inflammatory process – Balthazar's morphological index for acute pancreatitis		
Grade	Tomographic finding	Scoring
A	Normal pancreas.	0
B	Focal or diffuse pancreatic enlargement.	1
C	Pancreatic alterations associated with peripancreatic inflammation.	2
D	Single fluid collection.	3
E	Two or more fluid collections and/or presence of gas within the pancreas or within peripancreatic inflammation.	4
Pancreatic necrosis		
Tomographic finding		Scoring
Absence of necrosis.		0
< 30% necrosis.		2
30% to 50% necrosis.		4
> 50% necrosis.		6

Figure 3: Computed tomography severity index

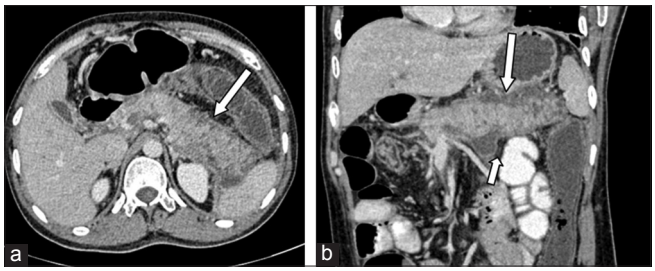

Figure 4: Contrast-enhanced computed tomography (CECT) in 45-year-old man with abdominal pain and raised amylase lipase. (a and b) Axial CECT venous phase image shows enlarged and edematous pancreas with loss of normal fatty lobulation and peripancreatic fat stranding, edema and free fluid (arrow, a). Coronal CECT venous phase image shows changes of acute edematous interstitial pancreatitis with extension of fluid noted in the lesser sac (long arrow, b) and along transverse mesocolon (short arrow, b)

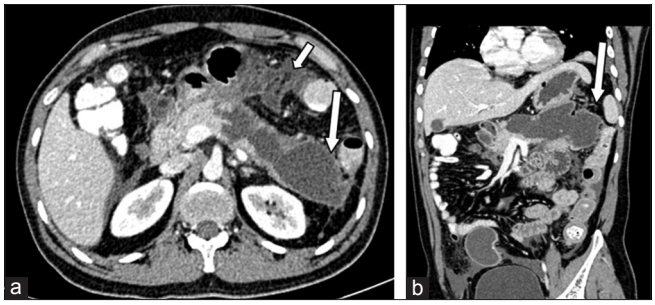

Figure 5: Contrast-enhanced computed tomography (CECT) in 34-year-old man with epigastric pain radiating to back. (a and b) Axial CECT venous phase image shows severely hypo/nonenhancing area suggestive of necrosis (long arrow, a) with >60% involvement with significant peripancreatic inflammation (short arrow, a). Coronal CECT venous phase image shows better delineation of extension of necrotic fluid throughout the body and tail of pancreas (long arrow, b)

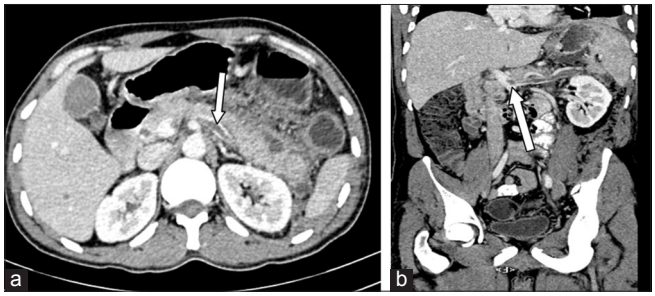

Figure 6: Contrast-enhanced computed tomography (CECT) in 28-year-old man with severe the upper abdominal pain. (a and b) Axial CECT, venous phase image, shows partially obstructing filling defect suggestive of thrombosis in the distal part of the splenic vein just before its confluence with superior mesenteric vein (long arrow, a). Changes of acute edematous interstitial pancreatitis are also seen. Coronal curved reconstruction image shows extent of the thrombus in entire splenic vein (long arrow, b)

if scans are performed 5-7 days after onset of symptoms. In necrotizing pancreatitis Revised Atlanta Classification identified three forms. In first one, there would be variable

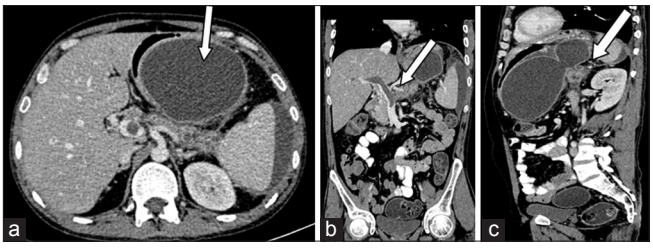

Figure 7: Contrast-enhanced computed tomography (CECT) in 32-year-old man with alcohol abuse, severe nausea, vomiting, and abdominal pain. (a, b and c) Axial CECT venous phase image shows a hypoattenuating collection suggestive of pseudo cyst formation anterior to the pancreas (long arrow, a). Coronal CECT venous phase image shows partially obstructing nonenhancing filling defect suggestive of acute thrombus is noted in the extrahepatic main portal vein (long arrow, b) Sagittal CECT venous phase image shows focal area of ductal disruption directly connecting with the pseudo cyst of pancreas (long arrow, c)

Figure 8: Contrast-enhanced computed tomography (CECT) in 41-year-old women with epigastric pain and altered pancreatic function test. a and b, oblique axial CECT venous phase image shows well encapsulated hypoattenuating lesion suggestive of walled-off pancreatic necrosis in the head and uncinate process of pancreas (long arrow, a). Coronal CECT venous phase image shows better delineation of the walled-off necrosis of pancreas 4 weeks after necrotizing pancreatitis

degree of necrosis which is seen as heterogeneous nonenhancing area (Figure 5) with or without minimal peripancreatic involvement. In the second form, there would be predominant extrapancreatic necrosis (Figure 6) with minimal parenchymal necrosis. The third form is the most common and shows variable degree and severity of pancreatic and extrapancreatic necrosis. Interstitial edematous pancreatitis is often associated with APFC which develop into pseudo cysts overtime (Figure 7). On the other hand, necrotizing pancreatitis is associated with pancreatic and extrapancreatic acute necrotic collection (ANC) which overtime develop into walled-off pancreatic necrosis (Figure 8). The ANC can get infected (abscess formation) (Figure 2). Air specks in the collection are most sensitive maker for abscess formations as is an enhancement of the walls of delayed phase image. Vascular thrombosis (Figure 6 and 7) and

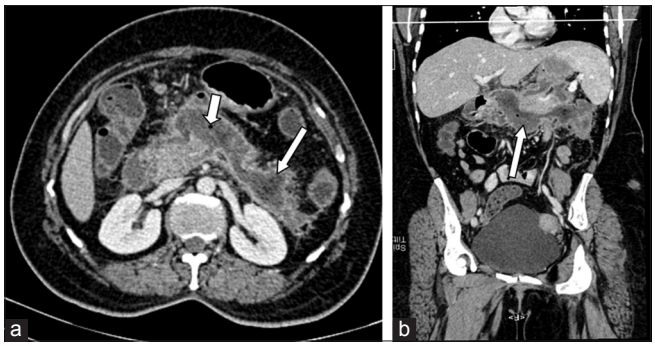

Figure 9: Contrast-enhanced computed tomography (CECT) in 22-year-old woman with fever and severe abdominal pain. (a and b), Axial and coronal CECT venous phase image shows severe necrosis of pancreas with parenchyma replaced by collection showing significant peripheral enhancement and few air specks (short arrow, a) within suggestive of pancreatic abscess formation (long arrows, a and b)

pseudoaneurysms can further complicate the course and natural prognosis of disease. Portal vein, splenic vein are more commonly involved than other vascular channels around (Figure 9).

In a study conducted by Cappell *et al.* acute pancreatitis was most common in 40-60 age groups. They also predicted the male to female predilection of 2:1.[11] In our present study, similar findings could be reported. Similarly, Bank *et al.* reported alcohol abuse in males and gallstones in females to be the most common etiopathological factor for this dreadful disease[9,11] Zhao *et al.*[12] published a reference to new Revised Atlanta Classification to bring down the inter observer reporting variations to describe and categorized disease with huge spectrum of involvement. Balthazhar *et al.* in formulated CTSI criteria to prognosticate the disease.[1,2,3,5] Many authors including Ju *et al.* have emphasized that USG and MRI have limited advantages over CT imaging.[8] We have successfully re-emphasized the findings coated by Balthazar *et al.*[6] on the extreme utility of CT imaging in acute pancreatitis. CTSI is clearly superior to Ranson criteria and APACHE scoring system in predicting outcome in acute pancreatitis.[7] There are limitations to our study as we have not included cases of acute on chronic pancreatitis which might altered the results of spectrum of involvement. We also do not have follow-up of patients clinical course, extent of morbidity and mortality after the scan was performed.

CONCLUSION

There is considerable utility of Triphasic contrast enhanced CT scan for evaluation of pancreas during its acute inflammation and follow-up to rule out complications of the same. Easy availability, multiplanar capabilities fast scanning techniques, have surely played major role in understanding changes in inflammation of pancreas during acute inflammation and to follow-up to know the extent of complication and thus predicting the morbidity and mortality of the disease thus helping the clinicians for proper counseling of the patient and their families. In view of wide spectrum of findings. CT scans have helped us to accurately stage the disease with high accuracy. CT remains a gold standard and sensitive modality for detection, accurate diagnosis and determine for exact extent of complication of acute pancreatitis. Predicting morbidity and mortality have proved to be more sensitive than the clinical criteria on the bases of CTSI.[1] Thus, CT has an extreme utility without any doubt in evaluating disease of acutely inflamed pancreas with its early and remote noninvasively.

REFERENCES

1. Balthazar EJ, Robinson DL, Megibow AJ, Ranson JH. Acute pancreatitis: Value of CT in establishing prognosis. Radiology 1990;174:331-6.
2. Casas JD, Díaz R, Valderas G, Mariscal A, Cuadras P. Prognostic value of CT in the early assessment of patients with acute pancreatitis. AJR Am J Roentgenol 2004;182:569-74.
3. Balthazar EJ. Acute pancreatitis: Assessment of severity with clinical and CT evaluation. Radiology 2002;223:603-13.
4. Shyu JY, Sainani NI, Sahni VA, Chick JF, Chauhan NR, Conwell DL, *et al.* Necrotizing pancreatitis: Diagnosis, imaging, and intervention. Radiographics 2014;34:1218-39.
5. Alhajeri A, Erwin S. Acute pancreatitis: Value and impact of CT severity index. Abdom Imaging 2008;33:18-20.
6. Balthazar EJ, Ranson JH, Naidich DP, Megibow AJ, Caccavale R, Cooper MM. Acute pancreatitis: Prognostic value of CT. Radiology 1985;156:767-72.
7. Triantopoulou C, Lytras D, Maniatis P, Chrysovergis D, Manes K, Siafas I, *et al.* Computed tomography versus acute physiology and chronic health evaluation II score in predicting severity of acute pancreatitis: A prospective, comparative study with statistical evaluation. Pancreas 2007;35:238-42.
8. Ju S, Chen F, Liu S, Zheng K, Teng G. Value of CT and clinical criteria in assessment of patients with acute pancreatitis. Eur J Radiol 2006;57:102-7.
9. Bank S, Indaram A. Causes of acute and recurrent pancreatitis. Clinical considerations and clues to diagnosis. Gastroenterol Clin N Am 1999;28:571-89, viii.
10. Bollen TL. Acute pancreatitis: International classification and nomenclature. Clin Radiol 2016;71:121-33.
11. Cappell MS. Acute pancreatitis: Etiology, clinical presentation, diagnosis, and therapy. Med Clin North Am 2008;92:889-923, ix-x.
12. Zhao K, Adam SZ, Keswani RN, Horowitz JM, Miller FH. Acute pancreatitis: Revised atlanta classification and the role of cross-sectional imaging. AJR Am J Roentgenol 2015;205:W32-41.

How to cite this article: Mudalgi B, Kachare M, Kulkarni A. Utility of 128-slice Multi-Detector Spiral Computed Tomography in Detecting Spectrum of Involvement in Acute Pancreatitis. Int J Sci Stud 2017;5(4):145-150.

Source of Support: Nil, **Conflict of Interest:** None declared.