Case Report

DOI: 10.17354/ijss/2015/90

Pre Endodontic Build-up of a Grossly Destructed Tooth: A Case Report

Shirin Kshirsagar[1], Shalini Aggarwal[2], Alia Mukhtar[1], Pooja Gupta[1], Vinay Rai[1], Monika Chawla[1]

[1]PostGraduate Student, Department of Conservative Dentistry and Endodontics Dr. D.Y.Patil Dental College and Hospital Pimpri, Pune, Maharashtra, India, [2]Professor, Department of Conservative Dentistry and Endodontics Dr. D.Y.Patil Dental College and Hospital Pimpri, Pune, Maharashtra, India

Abstract

Tooth structure loss due to caries or trauma often will hamper the required isolation with a rubber dam during root canal treatment. Improper isolation is one of the important reasons for compromised root canal therapy. The few minutes spent placing a build-up prior to the initiation of root canal therapy will help to achieve maximum positive result of treatment. The time investment will result in easy rubber dam placement, the adequate amount of achieved isolation, the reduced chance of losing the provisional restoration, and the superior quality of the end odontic treatment. Hence in this presentation, we will be reviewing the technique of restoring grossly decayed teeth prior to starting endodontic therapy. We are also showcasing cases of composite core build-up on grossly decayed teeth.

Keywords: Cariously destructed teeth, Core build up, Pre endodontic build up

INTRODUCTION

One of the main principles of endodontic therapy is disinfection of the root canal space. This disinfection is achieved by a three pronged approach, *viz*. cleaning and shaping, irrigation of the root canal space and usage of intra-canal medicaments. Achieving thorough debridement of the canal space is possible only when these modalities succeed. Having an access cavity that is four walled goes a long way in helping these goals to succeed. The dichotomy here is that very often the very teeth that need root canal therapy are also those that have lost a substantial amount of tooth structure.[1] These teeth almost never have intact crowns and at other times could also have old leaky restorations that need removal and hence we are faced with a further weakened tooth that does not lend itself to the application of a rubber dam clamp. These teeth that require root canal therapy thus need to be "pre-treated" before they can be subjected to root canal therapy. Doing this enables not only efficient disinfection but also application of the rubber dam sturdily over the tooth being treated.[2]

Access this article online

IJSS

www.ijss-sn.com

Month of Submission : 12-2014
Month of Peer Review : 01-2015
Month of Acceptance : 01-2015
Month of Publishing : 02-2015

The Pre-treatment Triad then consists of:
1. Removal of carious tooth structure.
2. Removal of old restorations.
3. Restoring contour of the tooth.

Completion of these steps fulfills the following objectives:
1. It prevents contamination of the root canal space by bacteria present in the carious lesions.
2. It prevents inter-appointment contamination of the canal space by oral fluids and saliva.
3. This also allows the intracanal medicaments to function to their optimum best. At the same time, the medicaments do not leach out into the oral cavity. This ensures that the root canal space remains in a medicated state in between appointments.
4. Having four good walls enables the tooth to sustain the forces exerted by a rubber dam clamp.
5. Reconstruct the pulp chamber so that there is an adequate space for the irrigating solutions and temporary medications. One must recall that, During the cleaning and shaping procedure, the pulp chamber must never be dry; on the contrary, it must contain as much irrigating solution as possible. The access cavity, therefore, must function as a basin, which is

Corresponding Author: Dr. Shirin Kshirsagar, Dr. D.Y.Patil Dental college and Hospital, Pimpri, Pune, Maharashtra, India.
Phone: +91 8411912525. E-mail: shirinkshirsagar87@gmail.com

possible only if there are four walls. The temporary medication must never be placed within the canal, but in the pulp chamber; For this reason, it requires space.

6. Re-establish a regular and stable contour of the tooth, to provide regular and easily locatable reference points by which one can determine, with the use of rubber stops, the working length of the instruments.
7. A meticulous pre-operative tooth build-up shall prevent a post-operative tooth fracture and improve the prognosis of the treatment.

This article presents clinical cases that have been restored pre-operatively.

CASE REPORT

A 24-year-old male patient came to clinics with a chief complaint of incomplete treatment done with the tooth in lower right back region of the jaw.

Clinical examination revealed badly carious tooth with the distal pulp horn exposed and carious lesion present on the distal and lingual surface (Figure 1).

Figure 1: Broken down mandibular molar

The pre-treatment radiograph revealed deep occlusal caries involving enamel, dentin and exposure of the pulp chamber with 46. It was seen that the pulp horn was involved and that there was a periapical lesion with the mesial root and a periodontal ligament widening with the distal root (Figure 2).

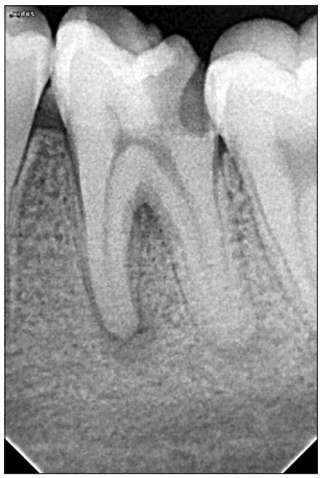

Figure 2: Pre-treatment IOPA of 46

After the evaluation of the radiograph, it was decided to do the root canal treatment of 46.

Clinical evaluation showed destruction of more than 2 walls of the tooth structure and it was anticipated that there would be a problem in putting on the rubber dam clamp for isolation. So, pre-endodontic build-up of lost tooth structure was the preferred option.

As the tooth was non-vital and asymptomatic local anesthesia was not given to the patient.

An access opening of the tooth in question was completed. During the access opening all the remaining carious tooth structure was removed (Figure 3).

Figure 3: Complete access opening with removal of caries

After the removal of the carious tooth structure, the tooth was deemed to have a tooth restorability index of >2.

During access opening four canal orifices were found. The orifices were enlarged using Sx ProTaper™. All the pulp tissue was extirpated from the pulp chamber and canals. 3% sodium hypochlorite and 17% ethylenediaminetetraacetic acid were used to irrigate the root canals.

The tooth structure was etched with 37% phosphoric acid for 15 s and it is rinsed with water and dried with blotting papers (Figure 4).

Later the tooth structure is coated with bonding agent (3M ESPE, single bond 2) in two layers and is cured for 20 s respectively (Figures 5 and 6).

After bonding to avoid destroying the canal entries with the restorative material during build-up the area of orifices are secured with the help of sterile cotton pellet (Figure 7).

After the cotton pellet is inserted, Tofflemire™ band is fitted around the tooth with the help of a retainer (Figure 8).

The stepwise core build up was done with the tooth using packable composite (3M ESPE, Filtek™ Z250 Universal) (Figures 9-11).

After the removal of band and retainer, all the ragged borders are made smooth with the help of composite polishing burs and stones (Figure 12).

The tooth structure, which was available after treatment was perfect for application of rubber dam (Figure 13).

Figure 4: Etching enamel and dentin

Figure 5: Application of bonding agent to etched tooth structure

It provided the maximum area for pooling of irrigating solution. Furthermore, it gave a four walled structure in which interappointment temporary restoration could be placed securely, which is very important for successful treatment outcome. It also helped to retain the intra canal medicament (R C Cal, Prime Dental). Temporization was done using Cavit™ (3M ESPM).

DISCUSSION

The aim of endodontic therapy is to clean and shape the root canal in order to obtain a tridimensional sealing of the endodontic space.[1]

One of the most critical elements in endodontic treatment is proper tooth isolation.[2]

Rubber dam is the most comfortable means of isolation among all isolation procedures. It was developed in 19th century by S. C. Barnum and became one of

Figure 6: Curing of bonding agent

Figure 7: Cotton pallet is used to avoid the blockage of canal orifice

Figure 8: Application of Tofflemire™ band and retainer

Figure 9: Step wise composite build-up

Figure 10: Step wise composite build-up

Figure 11: Step wise composite build-up

Figure 12: Finished restoration

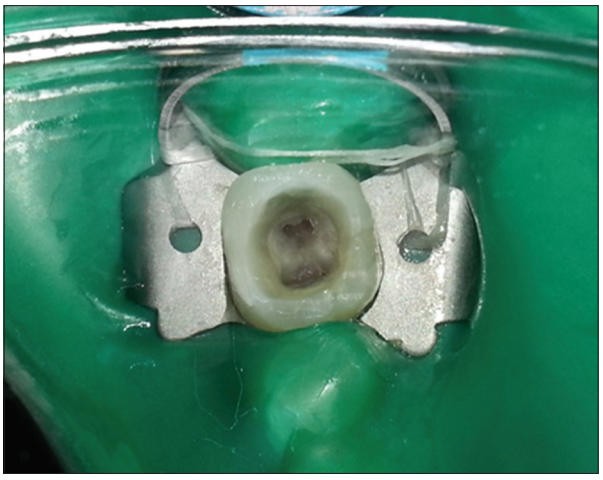

Figure 13: Built tooth with rubber dam and clamp

sophistication for the ultimate protection of both patient and clinician.

Properly placed rubber dam isolates the working area and avoid hindrance from obstacles like saliva and tongue.

Following are the advantages offered by a rubber dam:

1. Helps to achieve surgically clean operating field
2. Reduced chances of cross infection
3. Soft tissue is retracted and protected

4. Avoid aspiration of clamps or instrument by the patient
5. Increased access to working area.[3]

However all of this is possible if destructed tooth is built to secure the rubber dam clamp.

The working length of the tooth is defined as "the distance from a coronal reference point at which canal preparation and obturation should terminate.[4]"

Getting a proper and stable reference point is mandatory to have exact working length during complete root canal treatment. Build-up done on cariously destructed tooth helps to get the reference point during treatment.

Removal of the carious dentin and fractured over hanging restoration before build-up is necessary because it may hamper bond between tooth structure and composite and may also lead to secondary caries.[5]

Different materials are used to do pre-endodontic build up, e.g. Flowable composite, packable composite, self-cure or light-cure Glass-ionomer cement.[6]

If the tooth is going to be prepared for a crown, the build-up is ground from the inside. The purpose is to leave 0.5-0.7 mm to serve as a matrix for the final build-up. Then, during the crown preparation the build-up leftovers are removed.

The bonding procedure followed is always the total-etch procedure with selective enamel etching for 30 s. Then applying the bonding agent, which can be a two-bottle system or a self-priming single bottle system.[6]

In above case during build-up the obliteration of the canal orifice is protected by using a cotton pellet in the pulp chamber. Thermoplasticized GP pellets, LC Block-Out resin (Ultradent Products, Inc.), paper points also can be used for the same.[1]

The contact points between adjacent teeth should be respected when possible. The pre-endodontic build-up onrontal teeth should be made using the appropriate shades for the tooth so that the build-up will be as aesthetic as possible.[6]

CONCLUSION

In endodontic treatment, multiple variables can affect the outcome of a case. The use of this technique will enhance endodontic treatment by preventing marginal leakage before, during and after treatment that is provided before a final restoration is placed, facilitating treatment by increasing tooth surface area for clamp stability; and preventing further breakdown of the tooth by caries or fracture. By planning with a stable pre-endodontic restoration, the clinician is taking the first step toward a successful result.

REFERENCES

1. Cohen S, Burns RC. Pathways of the Pulp. 6th ed. St Louis: Mosby; 1994. p. 179-84.
2. Heydrich RW. Pre-endodontic treatment restorations. A modification of the 'donut' technique. J Am Dent Assoc 2005;136:641-2.
3. Hargreaves KH, Cohen S. Pathways of the Pulp.10th ed. St Louis: Mosby; 2010. p. 109.
4. Ingle JI, Bakland LK, Baumgartner JC. Ingle's Endodontics. 6th ed. Hamilton: BC Decker Inc.; 2008.
5. Omar H, El-Badrawy W, El-Mowafy O, Atta O, Saleem B. Microtensile bond strength of resin composite bonded to caries-affected dentin with three adhesives. Oper Dent 2007;32:24-30.
6. Kafelov B. Pre-endodontic Build-up: Methods and Applications; 2012.

How to cite this article: Kshirsagar S, Aggarwal S, Mukhtar A, Gupta P, Rai V, Chawla M. Pre Endodontic Build-up of a Grossly Destructed Tooth: A Case Report Int J Sci Stud 2015;2(11):225-229.

Source of Support: Nil, **Conflict of Interest:** None declared.