Print ISSN: 2321-6379
Online ISSN: 2321-595X
DOI: 10.17354/ijss/2016/627

Original Article

Pleomorphic Adenoma: An Observational Study

D C Sathyaki[1], R Gayathri[2], Mereen Susan Roy[1], H S Shruthi[1], Razal M Sheriff[2]

[1]Assistant Professor, Department of ENT, Sri Siddhartha Medical College, Tumkur, Karnataka, India, [2]Post-graduate Student, Department of ENT, Sri Siddhartha Medical College, Tumkur, Karnataka, India

Abstract

Background: Pleomorphic adenoma is the most common salivary gland tumor. The most common gland involved is parotid gland. It is more common in females. It is uncommon in submandibular and sublingual glands.

Objectives: Although pleomorphic adenoma is more common in parotid gland, it should be a part of differential diagnosis in submandibular swellings.

Materials and Methods: This was an observational study carried out in the Department of Otorhinolaryngology at our institute from February 2014 to June 2015. A total of 6 patients out of 3432 outpatients were included in the study. In the same period, 20 cases of pleomorphic adenoma were diagnosed in various departments of our institution.

Results: In our study, the age of patients varied between 20 and 60 years. They were no patients who were above 61 years. In this series, there were 50 female patients and 10 male patients. The odds ratio is 5.5, that is, females have 5.5 times more chances of getting pleomorphic adenoma as compared to males. Moreover, the Chi-square is statistically significant at $P < 0.0001$.

Conclusion: Pleomorphic adenomas are more common in parotid gland. Even though they are rare in submandibular gland, they should be considered as differential diagnosis in case of submandibular mass lesions. Pleomorphic adenomas are treated by complete surgical excision. Improper removal can result in recurrences.

Key words: Parotid, Pleomorphic Adenoma, Submandibular

INTRODUCTION

Salivary gland neoplasms account for 3% of all head and neck neoplasms. The overall incidence of salivary gland neoplasms is 4/100000/year, with the gender ratio being 1:1. Parotid gland is most commonly affected, followed by submandibular and minor salivary glands.[1] Neoplasms are more common in parotid and minor salivary glands, whereas non-neoplastic lesions are more common in submandibular salivary gland. Malignant neoplasms are more common in minor salivary glands, whereas benign neoplasms are more common in major salivary glands.[2]

The most common benign salivary gland tumor is pleomorphic adenoma. It is more common in parotid (57%), followed by minor (20%) and submandibular salivary glands (18%). The most frequent tumors of submandibular salivary gland are pleomorphic adenoma (36%), followed by adenoid cystic carcinoma (25%), mucoepidermoid carcinoma (12%), and malignant mixed tumors (10%).[1]

In this study, we present a series of pleomorphic adenomas who presented to our institution over a period of 1-year.

Access this article online

IJSS
www.ijss-sn.com

Month of Submission : 10-2016
Month of Peer Review : 11-2016
Month of Acceptance : 11-2016
Month of Publishing : 12-2016

MATERIALS AND METHODS

This was an observational study carried out in the Department of Otorhinolaryngology at our institute from February 2014 to June 2015. A total of 6 patients out of 3432 outpatients were included in the study. In the same period, 20 cases of pleomorphic adenoma were diagnosed in various departments of our institution.

Patients aged >16 years who presented with longstanding swelling in the head and neck region which was proven as pleomorphic adenoma by histopathological examination were included in the study.

Corresponding Author: Dr. D C Sathyaki, Sri Siddhartha Medical College, Agalakote, Tumkur, Karnataka, India. Phone: +91-9900284892. E-mail: sathyaki_dc@yahoo.co.in

The selected patients were subjected to detailed history, followed by complete clinical examination. All patients underwent either ultrasonography or computed tomography (CT) over the region of the swelling. They also underwent fine needle aspiration cytology of the swelling, and the diagnosis of pleomorphic adenoma was made. Patients later underwent surgical excision, and the diagnosis was confirmed by histopathology.

Procedures

All patients underwent surgical excision under general anesthesia. Patients with pleomorphic adenoma in the parotid gland superficial parotidectomy through standard parotidectomy approach. In case of submandibular gland, standard submandibular approach was followed.

RESULTS

In our study, the age of patients varied between 20 and 60 years. They were no patients who were above 61 years (Table 1).

In this series, three groups had 20 patients each. There was no patient belonging to the age group of 21-30 years.

The age group of outpatients during that period is given in Table 2.

The Chi-square test done shows the difference between the age group prevalence being not significant.

Sex Distribution

In this series, there were 50 female patients and 10 male patients (Table 3).

Sex distribution among our out patients is described in Table 4.

Table 1: Age group of Pleomorphic adenoma patients

Age group	No of cases	Percentage
21-30	Nil	0
31-40	20	33
41-50	20	33
51-60	20	33

Table 2: Age group of out patients

Age group	No. of out patients	Percentage	No of cases	Percentage
21-30	549	16	Nil	0
31-40	755	22	20	2.6
41-50	961	28	20	2.1
51-60	412	12	20	4.8
61<	755	22	Nil	0

The odds ratio is 5.5, that is, females have 5.5 times more chances of getting pleomorphic adenoma as compared to males. Moreover, the Chi-square is statistically significant at $P < 0.0001$.

Site Distribution

In this series, there were 55 patients with pleomorphic adenoma in the parotid gland and 5 in the submandibular salivary gland (Table 5) (Figures 1-5).

DISCUSSION

Salivary gland tumors are complex neoplasms which account for 3% of all head and neck tumours.[1] Benign/malignant ratio among major salivary glands is 2.1:1. Parotid gland is the most commonly affected among major salivary glands. Minor salivary glands are involved in 21.5% of the cases. Palate is the most common site affected.[3] Most common benign tumor is pleomorphic adenoma, followed by Warthin's tumor.[4] Most common malignant tumor is mucoepidermoid carcinoma, followed by adenoid cystic carcinoma.[5]

Pleomorphic adenoma is the most common neoplasm of salivary glands. It most commonly occurs in the fifth or sixth decade. It has female preponderance. It typically arises as a slow growing, firm mass that is slightly compressible. Almost all are asymptomatic and they are usually brought to the attention of the physician when routine physical examination is performed or when the patient feels or sees a lump. Imaging studies alone can provide a presumptive diagnosis. CT scan findings are tumors which are smooth and have well-defined margins. The attenuation values of the mass are usually

Table 3: Sex distribution of Pleomorphic adenoma patients

Sex	No of cases	Percentage
Males	10	16.7
Females	50	83.3

Table 4: Sex distribution of out patients

Sex	No of out patients	Percentage	No of cases	Percentage
Males	1842	53.7	10	0.54
Females	1590	46.3	50	3.1

Table 5: Site distribution

Site	No of cases	Percentage
Parotid	55	91.7
Submandibular	5	8.3

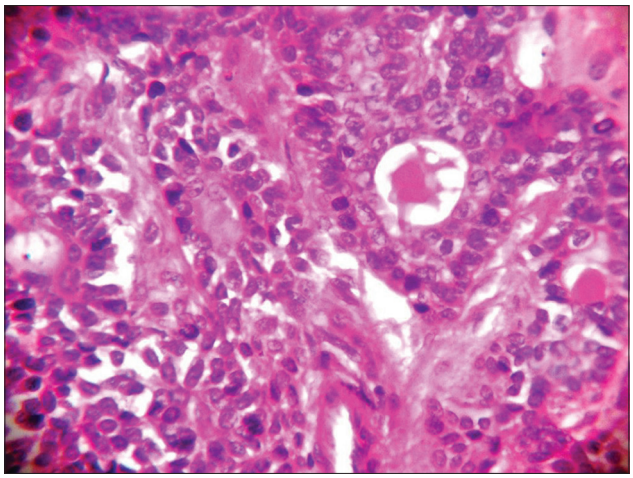

Figure 1: Myoepithelial cells (40×)

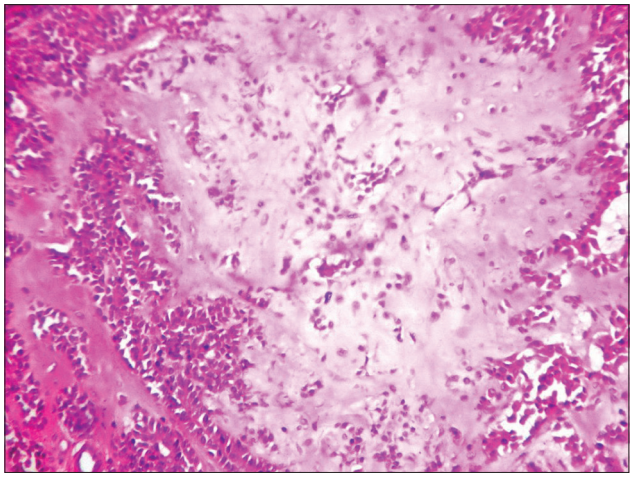

Figure 2: Myxoid matrix (40×)

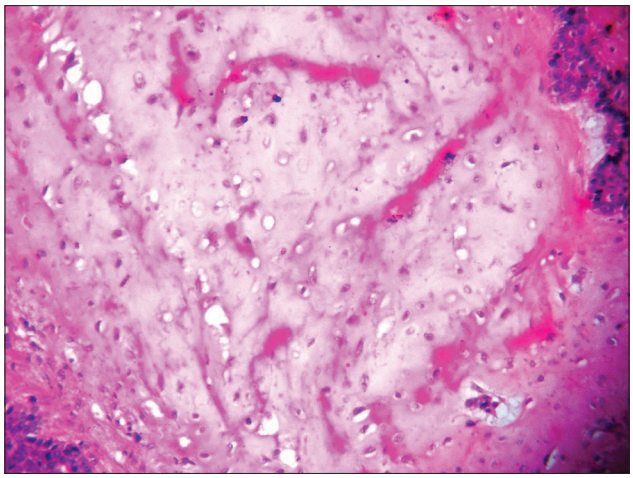

Figure 3: Pseudo cartilage (40×)

Figure 4: Submandibular swelling

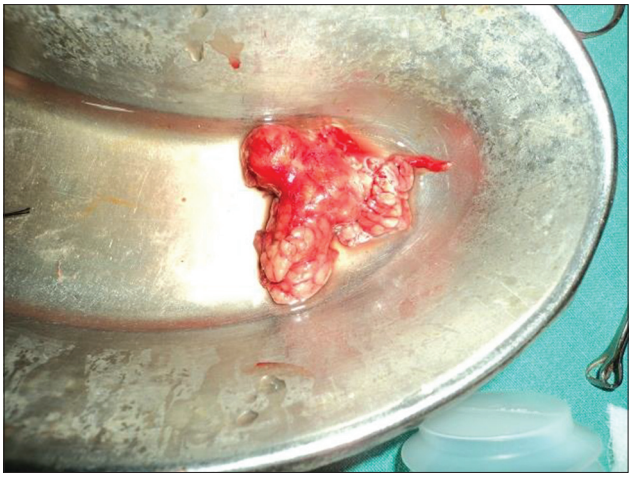

Figure 5: Gross specimen

homogeneous and higher than that of the surrounding gland. They typically show delayed contrast enhancement. When very large, they may develop a heterogeneous appearance with areas of necrosis, hemorrhage, cysts, and calcification. They are typically well demarcated from the surrounding tissue by a fibrous capsule, which varies both in thickness and completeness. This capsule is a result of fibrosis of surrounding salivary parenchyma, which is compressed by the tumor and is referred to as "false capsule." If the fibrous capsule can be completely removed, these tumors can be cured with surgery. The tumor also has small protrusions (pseudopodia) that extend beyond the central mass, caused by variability in the growth rates of the various cell types. This factor contributes to recurrence rates as high as 50%, depending on the type of surgical intervention. Microscopically, it is characterized by a myriad of morphological diversity. Epithelial cells are arranged in sheets and islands showing typical ductal structures and various epithelial and myoepithelial characteristics as spindle, clear, squamous, basaloid, plasmacytoid, oncocytic and sebaceous. The stroma characteristically is mixed with fibrous, chondroid, myxoid, or hyaline aspects. The incidence of malignant transformation in pleomorphic adenoma ranges from 1.9% to 23.3%.[6]

Ramirez *et al.* conducted a 10 year retrospective review of submandibular salivary gland tumors. They studied 22 cases of submandibular salivary gland neoplasms, out of which 19 cases were benign and 18 cases were pleomorphic adenoma. They concluded that pleomorphic adenoma was the most common submandibular salivary gland tumour.[1] Although it is the most common tumor of the submandibular salivary gland, 22 cases in 10-year period suggest that it is uncommon compared to other salivary glands. In our institution, we have reported the first case in this study.

Lawal *et al.* in their retrospective review of 413 cases of salivary gland neoplasms found only 49 neoplasms in submandibular salivary gland. Although pleomorphic adenoma was found to be the most common submandibular salivary gland neoplasm, it shows that neoplasms in submandibular glands are relatively uncommon.[2] The same message is conveyed through our study.

Sirohietal reported more common occurrence of pleomorphic adenoma in submandibular salivary gland than other tumors. However, neoplasms in submandibular salivary glands were relatively uncommon.[5]

Gupta *et al.* reported a giant pleomorphic adenoma of submandibular salivary gland which was 2.24 kg in weight. They concluded that it is very rare to find such a neoplasm in submandibular salivary gland.[6]

Rai *et al.* have reported an occurrence of pleomorphic adenoma of submandibular salivary gland. They also concluded that occurrence of pleomorphic adenoma in the submandibular salivary gland was uncommon.[7]

CONCLUSION

Majority of submandibular salivary gland swellings are either inflammatory or lithiasis. In such cases, there will be the presence of inflammatory signs such as tenderness, local rise of temperature, and redness over the skin. Absence of these signs points the diagnosis toward neoplasms. Pleomorphic adenomas are more common in parotid gland. Even though they are rare in submandibular gland, they should be considered as differential diagnosis in case of submandibular mass lesions. Pleomorphic adenomas are treated by complete surgical excision. Improper removal can result in recurrences.

REFERENCES

1. Becerril-Ramírez PB, Bravo-Escobar GA, Prado-Calleros HM, Castillo-Ventura BB, Pombo-Nava A. Histology of submandibular gland tumours, 10 years' experience. Acta Otorrinolaringol Esp 2011;62:432-5.
2. Lawal AO, Adisa AO, Kolude B, Adeyemi BF, Olajide MA. A review of 413 salivary gland tumours in the head and neck region. J Clin Exp Dent 2013;5:e218-22.
3. Zaib N, Mushtaq S, Mamoon N, Akhter N, Ayaz B. Immunohistochemical pattern of pleomorphic adenoma, polymorphous low grade adenocarcinoma and adenoid cystic carcinoma in minor salivary glands. J Dent (Tehran) 2014;11:38-46.
4. Laishram RS, Kumar KA, Pukhrambam GD, Laishram S, Debnath K. Pattern of salivary gland tumors in Manipur, India: A 10 year study. South Asian J Cancer 2013;2:250-3.
5. Sirohi D, Sharma R, Sinha R, Suresh Menon P. Salivary gland neoplasms: An analysis of 74 cases. J Maxillofac Oral Surg 2009;8:164-6.
6. Gupta M, Chaudhary N, Gupta M. Giant presentation of pleomorphic adenoma in major salivary gland. BMJ Case Rep 2011;40:1-3.
7. Rai S, Sodhi SP, Sandhu SV. Pleomorphic adenoma of submandibular gland: An uncommon occurrence. Natl J Maxillofac Surg 2011;2:66-8.

How to cite this article: Sathyaki DC, Gayathri R, Roy MS, Shruthi HS, Sheriff RM. Pleomorphic Adenoma: An Observational Study. Int J Sci Stud 2016;4(9):117-120.

Source of Support: Nil, **Conflict of Interest:** None declared.