Print ISSN: 2321-6379
Online ISSN: 2321-595X

Original Article

Current Scenario of Leprosy from a Referral Hospital, Tamil Nadu

Sudha Alagarsamy[1], Vidya Sundar Singh[2]

[1]Senior Assistant Professor, Department of Dermatology and STD, Govt. Theni Medical College Hospital, Theni, Tamil Nadu, India, [2]Senior Resident, Department of Dermatology and STD, Govt. Theni Medical College Hospital, Theni, Tamil Nadu, India

Abstract

Background: Leprosy, a chronic infectious disease, is a major public health concern in India. Thus, acquiring knowledge of its epidemiological variations is essential so that strategies for case detection and disease control can be made.

Aim: The objective of this study is to estimate the current scenario of leprosy from a referral hospital, Tamil Nadu.

Materials and Methods: Patients who attended dermatology department with signs and symptoms of leprosy from January 2016 to December 2019 were included in the study and their epidemiological and clinical profiles were recorded.

Results: A total of 212 patients were enrolled. Male/female ratio was 2.5:1. Majority of cases were between 41 and 60 years. Borderline tuberculoid was the most common type. Around 56% of patients had multibacillary (MB) leprosy. Lepra reactions were seen in 21.2% of cases and deformities were noticed in 15% of cases. Ulnar claw hand was the common deformity noted.

Conclusion: The number of new patients, MB proportion, and deformity among new patients were not in decreasing trend as expected in this post-elimination era. This highlights the urgent need for community-based appropriate strategy to break the chain in transmission of leprosy.

Key words: Deformity, Elimination, Leprosy, Multibacillary, Multidrug therapy, Reactions, World Health Organization

INTRODUCTION

Leprosy is one of the chronic infectious diseases that affect skin and peripheral nerves. *Mycobacterium leprae*, the causative organism, is transmitted by droplet spread which is facilitated by close contact.

Despite the prevalence rate being <1 case per 10,000 population, India still contributes more than 50% of new cases detected globally every year.[1] To understand the current trend of leprosy in post-elimination era, this study was conducted.

MATERIALS AND METHODS

This descriptive study was conducted in the Dermatology Department, Govt. Theni Medical College Hospital, Theni, Tamil Nadu, from January 2016 to December 2019.

Access this article online

IJSS

www.ijss-sn.com

Month of Submission : 11-2020
Month of Peer Review : 11-2020
Month of Acceptance : 12-2020
Month of Publishing : 01-2021

All patients who fulfilled the case definition of leprosy (one of the three cardinal features of leprosy) were included in the study. Age, sex, clinical spectrum of the disease, paucibacillary (PB) or multibacillary (MB), presence of lepra reaction, and disabilities were noted.

Clinical spectrum of the patient was decided after careful clinical examination, if needed also by slit skin smear examination and skin biopsy. The cases were divided into PB/MB according to the WHO criteria. (Number of skin lesions 1–5, with no nerve or only one nerve involvement with negative slit skin smear at all sites, was considered as PB, while number of skin lesions 6 and above with more than 1 nerve involvement with positive slit skin smear at any site was considered as MB).

Type I lepra reaction was diagnosed if the patient had redness, swelling (or) tenderness over the lesions, presence of edema of hands and feet or face, or tenderness of one or more nerves with or without nerve function impairment.

Type II lepra reaction was diagnosed if the patient had multiple, small, tender, evanescent nodules, or plaques with or without constitutional symptoms such as fever, malaise, and joint pain.

Corresponding Author: Dr. Sudha Alagarsamy, Department of Dermatology and STD, Govt. Theni Medical College Hospital, Theni, Tamil Nadu, India

For disability of hands and feet, the following World Health Organization (WHO) grading scale was used.
Grade 0: No anesthesia/no visible deformity.
Grade 1: Anesthesia present but no visible deformity.
Grade 2: Visible deformity/damage.

For disability of eyes also, the WHO grading scale was used.
Grade 0: No eye problems due to leprosy, no evidence of visual loss.
Grade1: Eye problem (corneal anesthesia, lagophthalmos, and iridocyclitis) due to leprosy present, but vision 6/60 or better, can count fingers at 6 m.
Grade 2: Severe visual impairment (vision worse than 6/60), inability to count fingers at 6 m.

Treatment was given according to the WHO recommendation to all patients.

RESULTS

In this 4 years study, we enrolled totally 212 patients. Year-wise total number of new cases ranged from 50 to 56 [Figure 1]. Maximum new cases were seen in 2019.

Out of 212 patients, 152 were male and 60 were female with male-female ratio of 2.5:1. Majority of cases were of the age group of 41–60 years (41%) followed by 21–40 years (36.3%), >60 years (14%), and 0–20 years (8.4%) [Table 1]. Seven patients were <15 years of age. Hence, child infection rate was 3.3%.

Total number of PB cases was 93 (43.8%) and MB cases were 119 (56.15%). The percentage MB cases in year 2016, 2017, 2018, and 2019 were 51.8% (28cases), 61.5% (32cases), 58% (29 cases), and 53.4% (30 cases), respectively [Figure 2].

One hundred and fourteen patients out of 212 (53.7%) were borderline tuberculoid type (BT) [Picture 1,2], 57 patients (26.8%) were borderline lepromatous (BL) [Picture 3,4], 14 patients (6.6%) were lepromatous leprosy (LL), 13 patients (6.1%) were tuberculoid leprosy, 8 patients (3.7%) were pure neuritic type, and 6 patients (2.8%) were histoid type [Picture 5] [Table 2].

Leprosy reactions were seen in 45 cases (21.2%) at the time of presentation, of which 37 cases (17.4%) were in Type 1 reaction [Picture 6] and 8 cases (3.8%) were in Type II reaction [Picture 7]. Year-wise comparison of Type I and II reaction is shown in Figure 3.

Grade 1 disability was seen in 46 cases (21.6%), Grade 2 disability was seen in 32 cases (15%), Grade 2 disability percentage in year 2016, 2017, 2018, and 2019 was 7.4% (4 cases), 17.3% (9 cases), 22% (11 cases), and 14.2% (8 cases), respectively [Figure 4].

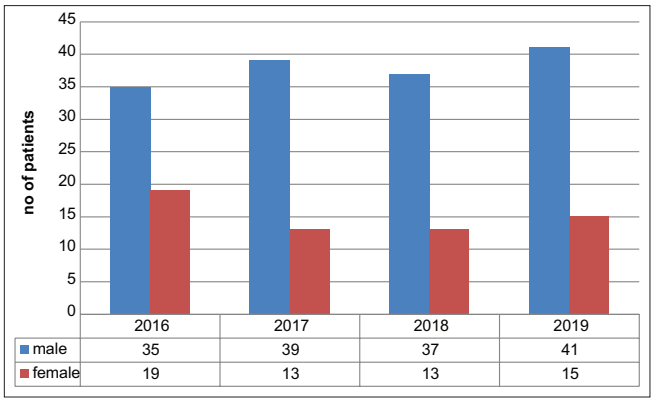

Figure 1: Sex-wise distribution

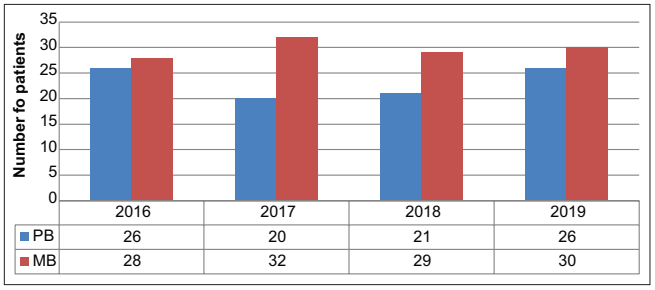

Figure 2: Paucibacillary versus multibacillary

Table 1: Age-wise distribution of patients

Age (years)	0–10		11–20		21–40		41–60		>60	
Sex	M	F	M	F	M	F	M	F	M	F
2016	-	1	3	1	13	10	14	7	5	-
2017	2	-	-	2	18	6	13	3	6	2
2018	-	-	3	3	14	2	15	6	5	2
2019	-	-	1	2	13	1	20	9	7	3

Among the deformity, ulnar claw hand was seen in 18 cases, total claw hand [Picture 8] in 6 cases, lagophthalmos [Picture 9] in 4 cases, foot drop in 2 cases, and auto-amputation of digits in 5 cases.

Nine patients gave a history of previous treatment for leprosy. Out of this, 6 patients were in BT spectrum. BL, pure neuritic, and histoid type were seen in one patient each.

DISCUSSION

In our study, males outnumbered females with male-female ratio of 2.5:1. According to National Leprosy Eradication Program (NLEP) annual report 2016–2017, female patients were 39.17% which is more than our statistics of 28.3%.[2] Majority of cases belong to the age group of 41–60 years in our study followed by 21–40 years. However, a study by Thyvalappil *et al.*[3] states common age group affected as

Table 2: Clinical spectrum of disease

Year	Tuberculoid leprosy		Borderline tuberculoid		Borderline lepromatous		Lepromatous leprosy		Pure neuritic		Histoid	
	M	F	M	F	M	F	M	F	M	F	M	F
2016	5	2	17	12	9	3	1	1	-	-	3	1
2017	3	1	14	8	13	4	4	-	4	-	1	-
2018	-	-	24	11	10	2	3	-	-	-	-	-
2019	1	1	19	9	13	3	5	-	2	2	1	-

Picture 1: Borderline tuberculoid leprosy (well to ill-defined coppery red hypoanesthetic patch with satellite lesion [arrow] seen)

Picture 3: Borderline lepromatous leprosy (multiple asymmetrical smooth shiny papules and nodules with indefinite edge)

Picture 2: Radial cutaneous nerve thickening

Picture 4: Greater auricular nerve thickening over the plaque lesion

20–40 years of age. Thus, the burden of the disease affects mainly the young productive male population of the society. Infection among <15 years of age was 3.3% in our study which is below the national level. It is because most of the children detected at school camp were given treatment by leprosy inspectors under the guidance of district officers.

In this study, a total of 119 patients (56.15%) were MB patients as per the WHO classification. According to NLEP 2016–2017 annual report, proportion of MB cases in India was 49.57% which is less than our statistics.[2] Over these years, the number of MB cases did not show a decreasing trend. High proportion of MB cases indicates late reporting for diagnosis and treatment.[4] This may also be due to difficult to access to services or inadequate public awareness. Another reason is due to shift from active to passive case detection.

The most commonly encountered type of leprosy in our study was BT followed by BL and LL. This is consistent with the study by Relhan *et al.*, 2016.[5] To our surprise, the severe form of leprosy (lepromatous and BL) was less common in females than males. In pure neuritic type, ulnar nerve was commonly involved followed by lateral popliteal nerve.

Picture 5: Histoid leprosy (firm erythematous dome-shaped shiny nodules)

Picture 6: Type I reaction (erythema and edema over borderline tuberculoid lesion)

Picture 7: Type II reaction – erythema nodosum leprosum (multiple erythematous tender evanescent nodules over back)

Forty-five patients (21.2%) were in reactional state at the time of diagnosis, of which Type I reaction was more common

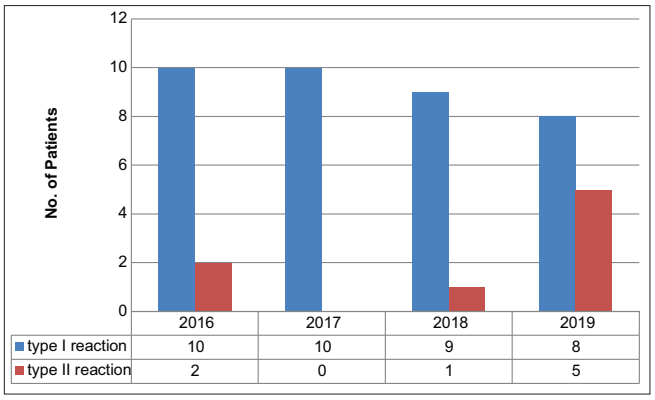

Figure 3: Comparison between Type I and Type II reaction

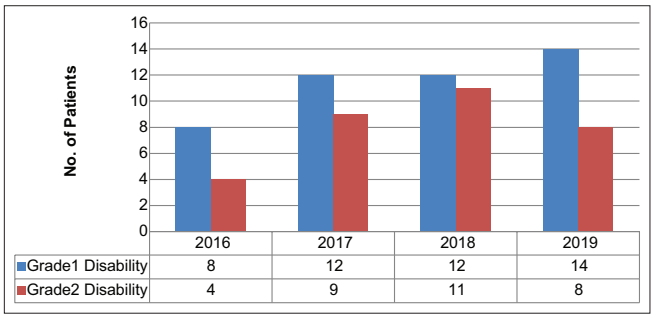

Figure 4: Disability severity

(17.4%). A study by Balagon *et al.* also shows a high proportion of patients with type I reaction at the time of diagnosis.[6]

Grade 2 disability (deformity) was seen in 32 cases (15% of total cases) in our study, whereas it was 34.78% in a study by Bhat and Chaitra.[7] Grade 2 disability also did not seem to decline over these years. Ulnar claw hand was the most common deformity noted. Persistence of high Grade 2 disability rate among new cases indicates that leprosy is being detected late and there may be hidden cases in the community.[8]

Those previously treated patients with new signs and symptoms of leprosy were mainly due to dapsone monotherapy or selection of incorrect multidrug therapy (MDT) regimen or poor patient compliance to treatment. Most of them were of BT spectrum and also responded well to restart of appropriate MDT regimen.

The knowledge about leprosy is poor among the affected individuals. Most of the cases came to us were referred by field health workers or referred from other departments for confirmation or incidentally we diagnosed as they attributed it to some other ailments.

Although there has been a significant reduction in prevalence of the disease worldwide since mid-1980s to elimination levels in December 2005, steady level of new cases indicates ongoing transmission.[9]

Picture 8: Total claw hand deformity

Picture 9: Lagophthalmos of the right eye

The WHO launched a 5-year "Global Leprosy Strategy 2016–2020" in April 2016 titled accelerating toward a leprosy-free world."[10]

It suggests,

1. Partnership with private sector including allopathic private practitioners for case detection/ referral, care, and social support of leprosy patients
2. Stop leprosy and its complications by strengthening patient and community awareness on leprosy, early case detection through special campaigns, ensuring prompt start and adherence to treatment, improving prevention and management of disabilities
3. Stop discrimination and promote inclusion by empowering leprosy affected persons in leprosy services, promoting access to social and financial support services.

CONCLUSION

In our study, males were more affected than females. Severity of the disease was less in females. BT type was commonly seen. The number of new cases, MB proportion, and deformity percentage did not show decreasing trend through the study years.

Based on this observation, we conclude that there is a need for wider awareness about signs and symptoms of leprosy and reactions among general health-care staffs as well as in the community to promote self-reporting, as well as early diagnosis and proper management of the disease and its complications in an integrated setting. "Care after Cure" that includes management of trophic ulcers and other long-term complications must also be addressed.

We also emphasize the urgent need for community based studies for devising appropriate strategy to break the chain in transmission of leprosy.

REFERENCES

1. Sengupta U. Elimination of leprosy in India: An analysis. Indian J Dermatol Venereol Leprol 2018;84:131-6.
2. Ministry of Health and Family Welfare Government of India. NLEP Annual Report for the Year 2016-2017. New Delhi: Ministry of Health and Family Welfare Government of India; 2017.
3. Thyvalappil A, Pretty M, Anumod B, Ajayakumar S, Rajiv S, Joy B, *et al*. Current trends of leprosy in a tertiary care centre in North Kerala. Indian J Leprol 2019;91:175-83.
4. Daniel S, Arunthathi S, Rao PS. Impact of integration on the profile of newly diagnosed leprosy patients attending a referral hospital in South India. Indian J Leprol 2009;81:69-74.
5. Relhan V, Ghunawat S, Tenani A, Mittal S, Garget VK. Trends in profile of leprosy cases reporting to a tertiary care centre in Delhi during 2006-2015. Indian J Leprol 2016;88:217-25.
6. Balagon MF, Cellona RV, Abalos RM, Gelber RH, Saunderson PR. The efficacy of a four week ofloxacin containing regimen compared with standard WHO MDT in PB leprosy. Leprol Rev 2010;81:2733.
7. Bhat RM, Chaitra P. Profile of new leprosy cases attending South Indian referral hospital. ISRN Trop Med 2013;2013:579024.
8. Rao N, Suneetha S. Current situation of leprosy in India and its future implications. Indian Dermatol Online J 2018;9:83-9.
9. World Health Organization. Weekly Epidemiological Record No 35. Vol. 92. Geneva: World Health Organization; 2017. p. 501-20.
10. World Health Organization. Global Leprosy Strategy 2016-2020: Accelerating Towards a Leprosy Free World. New Delhi: World Health Organization, Regional Office for South East Asia; 2016.

How to cite this article: Alagarsamy S, Singh VS. Current Scenario of Leprosy from a Referral Hospital, Tamil Nadu. Int J Sci Stud 2021;8(10):37-41.

Source of Support: Nil, **Conflicts of Interest:** None declared.